

## Treatment of AVN using the induction chamber technique and a biological-based approach: Indications and clinical results



G.M. Calori<sup>a,\*</sup>, E. Mazza<sup>a</sup>, M. Colombo<sup>a</sup>, S. Mazzola<sup>a</sup>, G.V. Mineo<sup>b</sup>, P.V. Giannoudis<sup>c</sup>

<sup>a</sup> Orthopaedic Reparative Surgery Department, Orthopaedic Institute Gaetano Pini, University of Milan, Italy

<sup>b</sup> University Department of Orthopaedics, Orthopaedic Institute Gaetano Pini, University of Milan, Italy

<sup>c</sup> Academic Department of Trauma and Orthopaedics, School of Medicine, University of Leeds, Leeds, UK

### ARTICLE INFO

#### Article history:

Accepted 17 September 2013

#### Keywords:

Avascular necrosis  
AVN  
Mesenchymal stem cells  
Core decompression  
rhBMP  
Osteonecrosis  
Femoral head  
Early stage  
Autologous implantation  
Biological chamber

### ABSTRACT

**Objective:** To determine the efficacy of core decompression (CD) technique combined with recombinant morphogenetic proteins, autologous mesenchymal stem cells (MSCs) and xenograft bone substitute into the necrotic lesion of the femoral head on clinical symptoms and on the progression of osteonecrosis of the femoral head.

**Patients and methods:** A total of 38 patients (40 hips) with early stage osteonecrosis of the femoral head were studied over a 4-year period.

**Results:** CD technique combined with recombinant morphogenetic proteins, autologous MSCs and xenograft bone substitute was associated with a significant reduction in both pain and joint symptoms and reduced the incidence of fractural stages. At 36 months, 33 patients achieved clinical and radiographic healing.

**Conclusion:** This long-term follow-up study confirmed that CD technique combined with recombinant morphogenetic proteins, autologous MSCs and xenograft bone substitute may be an effective treatment for patients with early stage osteonecrosis of the femoral head.

© 2013 Elsevier Ltd. All rights reserved.

### Introduction

Avascular necrosis (AVN) of the femoral head is a common cause of hip disability that may progress to collapse of the femoral head and hip osteoarthritis in up to 80% of patients if left untreated [1]. Osteonecrosis is the biological death of bone, either partially or completely. It has a variety of potential causes, idiopathic, infective, traumatic, toxic or ischaemic.

Osteonecrosis of the femoral head typically affects patients in their third to fifth decades of life [2]. In the USA in the future, 10,000–20,000 patients are expected to develop femoral head osteonecrosis every year, with 70% of them being males aged 30–40 years old. Over 50% of these patients will develop the disease in both hips within two years [3].

Several risk factors have been reported to be associated with the development of AVN, including alcohol abuse, excessive use of corticosteroids, haemoglobinopathy, Gaucher's disease, pregnancy, coagulopathies, Caisson disease, organ transplantation, hyper-

baric exposure, inflammatory or autoimmune disease, antiretroviral therapy, smoking [4,5], cancer chemotherapy [6,7] trauma and other idiopathic mechanisms [8–10]. Despite the plethora of causative factors, the pathophysiology of AVN remains uncertain [11–13].

The factors that influence the progression of AVN from the appearance of the necrotic lesion to subchondral fracture and femoral head collapse are not yet fully understood, but size and stage of osteonecrosis have been shown to be predictive of the clinical outcome [14].

The pathogenesis of osteonecrosis is still unclear, but it can be seen as a vascular and bone disease. On one hand, the function of the capillaries that serve as a conduit for the stem cells and bone cells needed in the bone remodelling unit and providing blood supply could be altered by emboli or thrombosis [15,16]. On the other hand, autologous mesenchymal stem cells (MSCs) and osteoblasts that could potentially induce bone formation have been shown to be decreased in number and activity [17,18]. Moreover, osteocytes and bone-lining cells in the necrotic lesion and the proximal femur undergo apoptosis [19,20]. This altered bone remodelling may be associated with three different events in the pathogenesis of osteonecrosis: the appearance of osteonecrosis itself, the insufficient bone repair that occurs after osteonecrosis, and its evolution to the subchondral fracture.

\* Corresponding author at: Orthopaedic Reparative Surgery Department, G. Pini, University of Milan, P.za Cardinal Ferrari 1, 20122 Milan, Italy.  
Tel.: +39 02 58296903; fax: +39 02 58296905.

E-mail address: [gmc@studiocalori.it](mailto:gmc@studiocalori.it) (G.M. Calori).

The gold standard therapy for early stage osteonecrosis of the femoral head (stage I of the Ficat [21] classification) is a conservative treatment comprising a symptomatic therapy, electrostimulation or extracorporeal shockwave therapy (ESWT). For later stages of osteonecrosis (stages II–III of the Ficat [21] classification), therapy comprises surgical treatment, such as vascularised fibula grafting, core decompression (CD) technique or total hip arthroplasty (THA); surface replacement arthroplasty offers a minimally destructive procedure. When the joint is irreversibly compromised (stage V), the most effective treatment solution is total hip replacement [22–24].

CD is a widely accepted procedure for treatment of hip osteonecrosis in its early stages (before mechanical failure has occurred) [25–29]. The outcome of CD is not always satisfactory: the reconstruction of the necrotic area by this method may remain incomplete because of inadequate creeping substitution and bone remodelling [30]. This is attributed to the relative insufficiency of osteoprogenitor cells in the proximal femur of the osteonecrotic hip [31,32]. Recent pioneer studies by Hernigou et al. and Gangji et al. have shown the efficacy of implantation of autologous MSCs into the CD tract during early-stage AVN [33–36]. There is evidence to indicate that implanted MSCs promote both osteogenesis and angiogenesis in the femoral head [34,37]. These beneficial effects may be mediated, at least in part, by MSCs and endothelial precursor cells [37].

The efficacy of growth factors, particularly recombinant human bone morphogenetic protein (rhBMP)-7, in orthopaedic surgery has been shown in several clinical studies, including in the treatment of non-union and bone defects [38–40,51–53]. The purpose of the current study is to evaluate the results of treatment using a new biological-based approach. The aim of this retrospective clinical study is to examine the effectiveness of CD and implantation of MSCs and growth factors (rhBMP-7) with flexible xenograft bone substitute [41] for the treatment of early-stage AVN to create a biological chamber [42] based on the principles of the polytherapy [43–45].

## Patients and methods

### Study design

This retrospective clinical study of prospectively documented data was conducted in the Orthopaedic Institute G. Pini (Milan) on patients treated between March 2007 and June 2011. The objective of this study was to assess the efficacy of the diamond-based approach to bone regeneration following CD combined with implantation of MSCs and growth factors (rhBMP-7) with a xenograft (equine origin) bone substitute partially demineralised (flexible) for the treatment of early-stage AVN.

AVN was classified according to the Ficat [21] classification: stage 0: asymptomatic, normal MRI and radiograph; stage 1: normal or minor changes on plain radiograph and MRI, sometimes groin pain; stage 2: sclerosis, or cysts of femoral head with diffuse porosis, geographic defects on MRI; stage 3: pain and stiffness with radiation to knee and limp, radiographs and MRI show broken contour of the head; stage 4: collapse, flattened contour, decreased joint space and osteoarthritis (Fig. 1 and Table 1).

### Participants

Inclusion criteria were age greater than 18 years, clinical signs of hip pain and radiological features on the MRI scan of stages I–III osteonecrosis (Ficat [21] classification).

Exclusion criteria were pregnancy, active infection, skeletal immaturity, stage IV osteonecrosis, immunosuppressive drug therapy, history of inflammatory arthritis, hypersensitivity to

rhBMP-7, contraindication to bone marrow harvest, severe osteoporosis, neuromuscular deficits or physical condition that may interfere with the ability to limit the load, autoimmune disease, cancer near to the site of surgery, previous treatment with rhBMP and mental health problems.

### Procedure

Patients received antibiotic prophylaxis with 2 g cephalosporin when they arrived in the surgical room (i.e. before surgery), then 1 g cephalosporin at both 8 h and 16 h after surgery.

The first step of the procedure was bone-marrow blood aspiration. The patient was placed on the operating table in a supine position with arms stretched out to the sides. The needle for bone-marrow blood aspiration was introduced at the level of the anterior iliac crest and the bone marrow blood was aspirated. The second step of the procedure was CD. A c-arm fluoroscope was draped with a sterile sleeve and positioned over the hip region to enable an anteroposterior view. Under fluoroscopic control, a Kirschner wire was inserted in the direction of the osteonecrotic lesion; the access of the wire was controlled with the two standard fluoroscopic projection. When the Kirschner wire was positioned at the lesion site, a 2 cm incision was made laterally through the skin and the fascia at the level of, or just distal to, the greater trochanteric. With the help of the Kirschner wire and a soft tissue protector, an 8-mm reamer was then inserted under fluoroscopic control through the trochanter, the femoral neck, and the femoral head in the direction of the osteonecrotic lesion. This procedure was then repeated with a specially shaped 12-mm reamer for retrograde removal of the osteonecrotic lesion. The reamer was directed towards the necrotic zone until it reached the pathologic area without reaching the joint. Concentration of the bone marrow sample was achieved by washing using physiological water to remove bone spicules, fat and cellular debris.

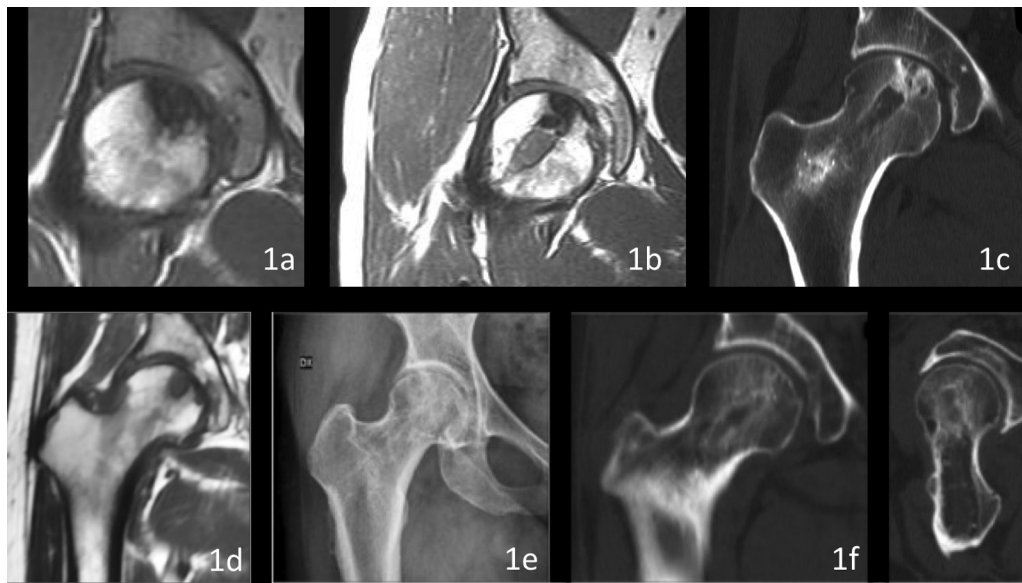
Growth factors (rhBMP-7), a scaffold of xenograft (equine origin) bone substitute and autologous bone MSCs was inserted inside the tunnel of the femur using special instrumentation; the bone substitute was inserted at the end to close all the components of the polytherapy [43–45] in the biological chamber [42]. The patient was usually discharged two days after surgery and was advised 20 days with no weight-bearing using two crutches, then 10 days with partial-weight bearing before returning to normal deambulation.

### Outcome assessments

Patients underwent clinical and radiological evaluation (X-ray, MRI, and CT scan) before surgery; then were classified using Ficat [21] classification. Follow-up was scheduled at 1, 3, 6, 9, 12, 24 and 36 months after the intervention. The primary outcome was clinical and comprised evaluation with the Harris hip score (HHS), which measures the pain, function, activity and motion of the hip. The secondary outcome was the radiological evaluation of the collapse of the femoral head. The tertiary outcome was the MRI–CT evaluation of the progression in osteonecrotic stages. The last outcome was the evaluation of the number of patients who went on to have a total hip replacement. Peri- and post-operative complications were recorded and classified as severe, moderate or mild. All adverse events were classified as serious or non-serious.

## Results

A total of 47 patients were enrolled in the current study between March 2007 and June 2011. Nine patients were lost to follow up, therefore 38 patients (40 hips) were available for the final follow up. Patients comprised 25 males and 13 females with a



**Fig. 1.** Two cases of AVN of the femoral head treated with our technique. (a–c) First patient, 33-year-old man. (a) MRI image showing the lesion; (b) MRI image of the femoral head 1 year after the procedure showing the implanted biotechnologies and the conserved shape of the femoral head; (c) CT scan after 3 years, good ossification of the subcondral bone, no trabecular collapse, shape of the femoral head still conserved. (d–f) second patient, 54-year-old woman. (d) MRI image showing the lesion; (e) X-ray at 2 years after the treatment, good integration of the biotechnologies implanted, no collapse; (f) CT scan after 3 years, no collapse, shape of the head conserved.

mean age of  $46.34 \pm 10.22$  years (minimum age 21 and maximum age 73); pathogenesis of the osteonecrosis included post-traumatic in four patients, long-term cortisone therapy in seven patients and idiopathic in 27 patients. According to the Ficat [21] classification criteria, there were seven hips with stage I osteonecrosis, 25 hips with stage II and eight hips with stage III.

Clinical and radiographic healing occurred in 33 of 38 patients (86.84%); the mean time to clinical success was  $1.8 \pm 0.99$  months. The radiological success was 86.84% at 36 months. The HHS was evaluated preoperatively and at 1, 12 and 36 months after surgery: the score was  $78.5 \pm 5.5$  pts preoperatively,  $82.97 \pm 5.1$  pts at 1 month and  $81.39 \pm 7.9$  pts at 36 months after the operation. In all the five failed treatments there was a collapse of the femoral head with progression of the osteonecrotic lesion at the 24 months' follow up. THA was performed in these patients. Notably, the failed treatment

could be associated with the complexity of the clinical situation of the hips of these patients, previously classified as stage III according to Ficat [21] classification. The only complications were four cases of calcification in the soft tissue near the surgery access and one subtrochanteric fracture of the femur 1 week after CD; in the latter case we proceeded with the reduction and synthesis with a nail and at the last follow-up at 36 months treatment success was noted.

## Discussion

The phenomenon of AVN was first described by Alexander Munro in 1738. At the end of 1800, the French anatomist Jean Baptiste Léon Cruveilhier proposed that bloodstream impairment of the femoral head was a possible cause. Much attention has been given by the scientific community to the early diagnosis of AVN

**Table 1**

The main studies about core decompression and biotechnologies implantation in the treatment of AVN of the femoral head and related results.

Authors	Treatment	Patients	Results
Hernigou P. and Beaujean F. (2002)	CD + autologous bone grafting	116 Patients (189 hips)	Clinical success in 155/189 hips
Lieberman J.R. et al. (2004)	CD + allogenic, antigen-extracted, autolysed fibula allograft + 50 mg partially purified human bone morphogenetic protein and non-collagenous proteins	15 Patients (17 hips)	Clinical success in 14/17 hips
Calori G.M. et al. (2008)	CD + growth factors + scaffold (tantalum screw)	18 Patients (19 hips)	Clinical success in 15/18 patients
Gangji V. et al. (2011)	11 hips: CD 13 hips: CD + implantation of bone marrow	19 Patients (24 hips)	Clinical success in 3/11 patients in CD group and in 10/13 patients in CD + implantation of bone marrow group
Yaosheng L. et al. (2012)	17 hips: CD 17 hips: CD + Implantation of bone MARROW mononuclear cell with porous hydroxyapatite composite filler	34 Patients (34 hips)	HHP score significantly increased in BMMC group; VAS score significantly decreased in BMMC group. Radiological and clinical success rates significantly higher in BMMC group (82.5 vs 40.7 and 75.4 vs 37.0)
Zhao D. et al. (2012)	47 hips: CD (7 hips lost follow-up) 53 hips: CD + implantation of bone marrow mesenchymal stem cells	100 Patients (100 hips)	Clinical success in 51/53 patients in CD + implantation of bone marrow mesenchymal stem cells and in 30/40 patients in CD group
Calori G.M. et al. (2013)	CD + recombinant morphogenetic proteins + autologous MSCs + xenograft bone substitute	34 Patients (40 hips)	Clinical success in 33/34 patients

and to optimisation of treatment modalities to avoid the final treatment option, which is total hip replacement.

The CD technique was first proposed by Arlet and Ficat in 1967, initially as a diagnostic procedure. This method is associated with a reduction in both symptomatology and disease progression. Possible mechanisms for the effectiveness of this therapy include a reduction in pressure inside the femoral head and an increase of blood flow. In Mont et al.'s [23] preclinical study, defects that were treated with bone graft and rhBMP-7 showed moderate to excellent healing radiographically and biomechanically; defects that were left untreated did not heal. Hernigou and Beaujean [34] reviewed 189 hips treated with autologous bone grafting and CD after an average follow-up period of 7 years; total hip replacement was performed in 34 hips (18%). The authors observed that the best results were achieved in hips that received increased numbers of osteoprogenitor cells.

Lieberman et al. [46] published the results of a retrospective evaluation of 15 patients (17 hips) with a diagnosis of symptomatic osteonecrosis of the hip treated with CD combined with an allogeneic, antigen-extracted, autolysed fibula allograft and 50 mg of partially purified hBMP and non-collagenous proteins. The average duration of clinical follow-up was 53 months (range 26–94 months). All the hips were evaluated and classified: 16 hips were classified according to the classification of Ficat as stage II and one hip as stage III. An involvement of 50% or less of the femoral head was observed in 14 hips. Clinical success was described in 14 out of 15 hips (93%, 13 patients) with stage II disease. In three out of 17 hips (three patients), there was a progression of necrosis evaluated radiographically (Ficat stages II and III) and these patients required total hip replacement surgery.

A particular treatment was ideated by Calori et al. [47] in which CD technique was used with growth factors and a scaffold, a Tantalum screw with osteoconductive properties. A total of 18 patients (19 hips) received this treatment. Healing, pain remission and interruption of osteonecrosis progression occurred in 15 patients.

Along with BMPs, surgeons have considered combining CD with autogenous MSCs, which represent osteoprogenitor cells with the power to enhance bone repair.

Gangji et al. [48] conducted a study on 24 hips with early stage osteonecrosis of the femoral head; the hips were allocated to either CD only (11 patients) or CD and implantation of bone marrow (13 patients). At 60 months, eight out of 11 hips in the control group had deteriorated to the fractural stage whereas only three of 13 hips in the bone marrow graft group had progressed to that stage. The results show that bone marrow implantation was associated with a significant reduction in both pain and joint symptoms and reduced the incidence of fractural stages.

A study by Liu et al. [49] reported success with CD and implantation of bone marrow mononuclear cells with porous hydroxyapatite composite filler in 17 patients compared with an equivalent group treated only with CD.

Similar results were reported by Zhao et al. [50]. They recruited and randomised 100 patients with early stage AVN into two treatment groups: one group received CD with implantation of bone marrow MSCs and the other only CD. Sixty months after the operation, only two of the 53 hips treated with CD and bone marrow MSCs progressed and underwent vascularised bone grafting. In the CD group, seven hips were lost to follow-up, and 10 of the remaining 44 hips progressed and underwent vascularised bone grafting or total hip replacement. The author reported that implantation of MSCs alongside CD significantly improved the HHS as well as decreased the volume of femoral head of the hips preoperatively classified at stage IC, IIB and IIIC (Steinberg classifications) compared with the CD group.

There are no reports of controlled clinical trials that evaluate the synergistic action between MSCs and rhBMP-7. There are two preclinical studies *in vitro* and *in vivo* that show the efficacy of this combination on animals. In humans there are only case reports.

We progressed to the next level of biological enhancement, based on the diamond concept of tissue engineering, to promote bone regeneration in an efficient manner and to minimise the risk of secondary collapse. Although the incidence of AVN is not high, it is associated with high morbidity. It often affects young patients, thereby leading to high social costs in terms of health and welfare. Total hip replacement, for example, is associated with significant long-term costs because of post-operative rehabilitation involving abstention from work for a few months and the need for revision surgery. The current clinical study is limited by the number of enrolled patients who reached the end of follow-up (36 months).

## Conclusions

We have shown that the CD technique with autologous bone marrow cells, growth factors (BMP-7) and flexible xenograft (equine origin) bone substitute implantation reduces the incidence of fractural stage non-traumatic osteonecrosis of the femoral head; delays the progression of stages I–II osteonecrosis, and decreases hip pain and joint symptoms. In selected cases, particularly in young patients, stage III lesions (Ficat classification) could be treated with our technique to avoid or delay a total hip replacement. To our knowledge, this is the first clinical study that associates autologous bone marrow cells, growth factors (BMP-7) and porous hydroxyapatite composite bone filler for the treatment of early osteonecrosis of the femoral head. Preliminary data indicate a therapeutic potential of BMPs in AVN.

## Conflicts of interest

The authors have no conflicts of interest to declare. No financial support has been received by the authors for the preparation of this manuscript.

## References

- [1] Mont MA, Rajadhyaksha AD, Hungerford DS. Outcomes of limited femoral resurfacing arthroplasty compared with total hip arthroplasty for osteonecrosis of the femoral head. *J Arthroplasty* 2001;16(8 Suppl 1):134–9.
- [2] Mont MA, Carbone JJ, Fairbank AC. Core decompression versus nonoperative management for osteonecrosis of the hip. *Clin Orthop Relat Res* 1996;324:169–78.
- [3] Aldridge III JM, Urbaniak JR. Avascular necrosis of the femoral head: etiology, pathophysiology, classification, and current treatment guidelines. *Am J Orthop* 2004;33:327–33.
- [4] Hirota Y, Hirohata T, Fukuda K, Mori M, Yanagawa H, Ohno Y, et al. Association of alcohol intake, cigarette smoking, and occupational status with the risk of idiopathic osteonecrosis of the femoral head. *Am J Epidemiol* 1993;137:530–8.
- [5] Matsuo K, Hirohata T, Sugioka Y, Ikeda M, Fukuda A. Influence of alcohol intake, cigarette smoking, and occupational status on idiopathic osteonecrosis of the femoral head. *Clin Orthop* 1988;234:115–23.
- [6] Kaila R, Wolman RL. Groin pain in athletes: a consequence of femoral head avascular necrosis after testicular cancer chemotherapy. *Clin J Sport Med* 2006;16(2):175–6.
- [7] Sakakura M, Nishii K, Usui E, Monma F, Tsukada T, Shiku H. Bilateral osteonecrosis of the head of the femur during treatment with retinoic acid in a young patient with acute promyelocytic leukemia. *Int J Hematol* 2006;83(3):252–3.
- [8] Ghosh J, Maniunatha YC, Thulkar S, Bakhshi S. Avascular necrosis of femoral head in childhood acute myeloid leukemia: complication of chemotherapy without steroids. *Pediatr Blood Cancer* 2008;51(2):308–9.
- [9] Gürkan E, Yildiz I, Oçal F. Avascular necrosis of the femoral head as the first manifestation of acute lymphoblastic leukemia. *Leuk Lymphoma* 2006;47(2):365–7.
- [10] Hughes C, Patterson K, Murray M. Avascular necrosis of the femoral head in childhood chronic myeloid leukaemia. *Br J Haematol* 2007;139(1):1.



- [11] Babhulkar S. Osteonecrosis of femoral head: treatment by core decompression and vascular pedicle grafting. *Indian J Orthop* 2009;43:27–35.
- [12] Jones KB, Seshadri T, Krantz R, Keating A, Ferguson PC. Cell-based therapies for osteonecrosis of the femoral head. *Biol Blood Marrow Transplant* 2008;14:1081–1087.
- [13] Marker DR, Seyler TM, Ulrich SD, Sirvastava S, Mont MA. Do modern techniques improve core decompression outcomes for hip osteonecrosis? *Clin Orthop Relat Res* 2008;466:1093–103.
- [14] Nam Kw, Kim YL, Yoo JJ, Koo KH, Yoon KS, Kim HJ. Fate of untreated asymptomatic osteonecrosis of the femoral head. *J Bone Joint Surg Am* 2008;90:477–84.
- [15] Jones Jr JP. Fat embolism and osteonecrosis. *Orthop Clin North Am* 1985;16:595–633.
- [16] Simkin PA, Downey DJ. Hypothesis: retrograde embolization of marrow fat may cause osteonecrosis. *J Rheumatol* 1987;14:870–2.
- [17] Gangji V, Hauzer JP, Schoutens A, Hinsenkamp M, Appelboom T, Egrise D. Abnormalities in the replicative capacity of osteoblastic cells in the proximal femur of patients with osteonecrosis of the femoral head. *J Rheumatol* 2003;30:348–51.
- [18] Hernigou P, Beaujean F. Abnormalities in the bone marrow of the iliac crest in patients who have osteonecrosis secondary to corticosteroid therapy of alcohol abuse. *J Bone Joint Surg Am* 1997;79:1047–53.
- [19] Calder JD, Pearse MF, Revell PA. The extent of osteocyte death in the proximal femur of patients with osteonecrosis of the femoral head. *J Bone Joint Surg Br* 2001;83:419–22.
- [20] Ko JY, Wang FS, Wang CJ, Wong T, Chou Wy, Tseng SL. Increased Dickkopf-1 expression accelerates bone cell apoptosis in the femoral head osteonecrosis. *Bone* 2010;46:584–91.
- [21] Ficat RP. Idiopathic bone necrosis of the femoral head: early diagnosis and treatment. *J Bone Joint Surg* 1985;67B:3–9.
- [22] Berend KR, Gunneson E, Urbaniak JR, Vail TP. Hip arthroplasty after failed free vascularized fibular grafting for osteonecrosis in young patients. *J Arthroplasty* 2003;18(4):411–9.
- [23] Mont MA, Jones LC, Elias JJ, Inoue N, Yoon TR, Chao EY, et al. Strut-autografting with and without osteogenic protein-1: a preliminary study of a canine femoral head defect model. *J Bone Joint Surg Am* 2001;83-A(7):1013–22.
- [24] Xenakis TA, Soucacos PN, Beris AE. Total hip arthroplasty in the management of osteonecrosis of the femoral head. In: Urbaniak JR, Jones Jr JP, editors. *Osteonecrosis: etiology, diagnosis and treatment*. Rosemont, IL: American Academy of Orthopaedic Surgeons; 1997. p. 391–6.
- [25] Hungerford DS. Treatment of osteonecrosis of the femoral head. *J Arthroplasty* 2007;22–4:91.
- [26] Lieberman JR. Core decompression for osteonecrosis of hip. *Clin Orthop* 2004;418:29.
- [27] Lorio R, Healy WL, Abramowitz AJ, Pfeifer BA. Clinical outcome and survivorship analysis of core decompression for early osteonecrosis of the femoral head. *J Arthroplasty* 2006;21–5:670.
- [28] Soohoo NF, Vyas S, Manunga J, Sharifi H, Kominski G, Lieberman JR. Cost effective analysis of core decompression. *J Arthroplasty* 2006;21–5:670.
- [29] Stulberg BN, Davis AW, Bauer TW, Levine M, Easley K. Osteonecrosis of the femoral head. A prospective randomized treatment protocol. *Clin Orthop* 1991;268:140–51.
- [30] Koo KH, Kim R, Ko GH, Song HR, Jeong ST, Cho SH. Preventing collapse in early osteonecrosis of the femoral head. A randomized clinical trial of core decompression. *J Bone Joint Surg Br* 1995;77–6:870–4.
- [31] Heringou P, Poignard A, Manicom O, Mathieu G, Rouard H. The use of percutaneous autologous bone marrow transplantation in nonunion and avascular necrosis of bone. *J Bone Joint Surg Br* 2005;87–7:896–902.
- [32] Hernigou P, Beaujean F, Lambotte JC. Decrease in the mesenchymal stem cell pool in the proximal femur in corticosteroid induced osteonecrosis. *J Bone Joint Surg Br* 1999;81–2:349–55.
- [33] Gangji V, Hauzer JP, Matos C, De Maertelaer V, Toungouz M, Lambermont M. Treatment of osteonecrosis of the femoral head with implantation of autologous bone marrow cells. A pilot study. *J Bone Joint Surg Am* 2004;86–A: 1153–60.
- [34] Hernigou P, Beaujean F. Treatment of osteonecrosis with autologous bone marrow grafting. *Clin Orthop Relat Res* 2002;405:14–23.
- [35] Hernigou P, Poignard A, Zilber S, Rouard H. Cell therapy of hip osteonecrosis with autologous bone marrow grafting. *Indian J Orthop* 2009;43:40–5.
- [36] Rackwitz L, Eden L, Reppenhausen S, Reichert JC, Jakob F, Walles H, et al. Stem cell- and growth factor-based regenerative therapies for avascular necrosis of the femoral head. *Stem Cell Res Ther* 2012;3(1):7.
- [37] Sun Y, Feng Y, Zhang C. The effect of bone marrow mononuclear cells on vascularization and bone regeneration in steroid-induced osteonecrosis of the femoral head. *Joint Bone Spine* 2009;76:685–90.
- [38] Calori GM, Tagliabue L, Gala L, d'Imporzano M, Peretti G, Albisetti W. Application of rhBMP-7 and platelet-rich plasma in the treatment of long bone non-unions: a prospective randomized clinical study on 120 patients. *Injury* 2008;39(12):1391–402.
- [39] Kanakaris NK, Lasanianos N, Calori GM. Application of bone morphogenetic proteins to femoral non-unions: a 4-year multicentre experience. *Injury* 2009;40(S3):S54–60.
- [40] Kanakaris NK, Calori GM, Verdonk R, Burssens P, De Biase P, Capanna R, et al. Application of BMP-7 to tibial non-unions: a 3-year multicenter experience. *Injury* 2008;39(S2):S83–90.
- [41] Calori GM, Mazza E, Colombo M, Ripamonti C. The use of bone graft substitutes in large bone defects: any specific needs? *Injury* 2011;42(Suppl 2):S56–63.
- [42] Calori GM, Giannoudis PV. Enhancement of fracture healing with the diamond concept: the role of the biological chamber. *Injury* 2011;42(11):1191–3.
- [43] Calori GM, Mazza E, Colombo M, Ripamonti C, Tagliabue L. Treatment of long bone non unions with polytherapy: indications and clinical results. *Injury* 2011;42(6):587–90.
- [44] Calori GM, Colombo M, Ripamonti C, Bucci M, Fadigati P, Mazza E, et al. Polytherapy in bone regeneration: clinical applications and preliminary considerations. *Int J Immunopathol Pharmacol* 2011;24(S2):85–9.
- [45] Calori GM, Colombo M, Mazza E, Ripamonti C, Mazzola S, Marelli N, et al. Monotherapy vs. polytherapy in the treatment of forearm non-unions and bone defects. *Injury* 2013;44(S1):S63–9.
- [46] Lieberman JR, Conduah A, Urist MR. Treatment of osteonecrosis of the femoral head with core decompression and human bone morphogenetic protein. *Clin Orthop Relat Res* 2004;429:139–45.
- [47] Calori GM, Mazza E, Tagliabue L. Management delle osteonecrosi avascolari della testa del femore con fattori di crescita. *Aggiorn Club Ita Osteosint* 2008;14:S131–5.
- [48] Gangji V, De Maertelaer V, Hauzeur JP. Autologous bone marrow cell implantation in the treatment of non traumatic osteonecrosis of the femoral head: five year follow up of a prospective controlled study. *Bone* 2011;49: 1005–9.
- [49] Liu Y, Liu S, Su X. Core decompression and implantation of bone marrow mononuclear cells with porous hydroxylapatite composite filler for the treatment of osteonecrosis of the femoral head. *Arch Orthop Trauma Surg* 2012;133:125–33.
- [50] Zhao D, Cui D, Wang B, Tian F, Guo L, Yang L, et al. Treatment of early stage osteonecrosis of the femoral head with autologous implantation of bone marrow-derived and cultured mesenchymal stem cells. *Bone* 2012;50: 325–30.
- [51] Papanna MC, Al-Hadithy N, Somanchi BV, Sewell MD, Robinson PM, Khan SA, et al. The use of bone morphogenetic protein-7 (OP-1) in the management of resistant non-unions in the upper and lower limb. *Injury* 2012;43(7 (July)): 1135–40.
- [52] Blokhuis TJ, Calori GM, Schmidmaier G. Autograft versus BMPs for the treatment of non-unions: what is the evidence? *Injury* 2013;44(Suppl 1 (January)): S40–2.
- [53] Ronga M, Fagetti A, Canton G, Paiusco E, Surace MF, Cherubino P. Clinical applications of growth factors in bone injuries: experience with BMPs. *Injury* 2013;44(Suppl 1 (January)):S34–9.