



# Application of rhBMP-7 and platelet-rich plasma in the treatment of long bone non-unions

## A prospective randomised clinical study on 120 patients

G.M. Calori<sup>a,\*</sup>, L. Tagliabue<sup>c</sup>, L. Gala<sup>b</sup>, M. d'Imporzano<sup>a</sup>,  
G. Peretti<sup>b</sup>, W. Albisetti<sup>b</sup>

<sup>a</sup> Orthopaedic Institute, G. Pini University of Milan, Italy

<sup>b</sup> Institute of Orthopaedic, Trauma, Rheumatology Sciences, Orthopaedic Rehabilitation Institute, University of Milan, Italy

<sup>c</sup> Biomaterials Research Centre (C.R.S.B.), University of Milan, Italy

Accepted 15 August 2008

### KEYWORDS

rhBMP-7;  
PRP;  
Long bones;  
Non-union;  
Bone healing

**Summary** The purpose of this prospective randomised clinical study was to compare the efficacy of recombinant bone morphogenetic protein 7 (rhBMP-7) and platelet-rich plasma (PRP) as bone-stimulating agents in the treatment of persistent fracture non-unions.

One hundred and twenty patients were randomised into two treatment groups (group rhBMP-7 vs. group PRP). Sixty patients with sixty fracture non-unions were assigned to each group (median age: 44 years, range 19–65, for the rhBMP-7 group and 41 years, range 21–62, for the PRP group, respectively). In the rhBMP-7 group, there were 15 tibial non-unions, 10 femoral, 15 humeral, 12 ulnar, and 8 radial non-unions. In the PRP group, there were 19 tibial non-unions, 8 femoral, 16 humeral, 8 ulnar, and 9 radial non-unions. The median number of operations performed prior to our intervention was 2 (range 1–5) and 2 (range 1–5) with autologous bone graft being used in 23 and 21 cases for the rhBMP-7 and PRP groups, respectively.

Both clinical and radiological union occurred in 52 (86.7%) cases of the rhBMP-7 group compared to 41 (68.3%) cases of the PRP group, with a lower median clinical and radiographic healing time observed in the rhBMP-7 group (3.5 months vs. 4 months and 8 months vs. 9 months, respectively). This study supports the view that in the treatment of persistent long bone non-unions, the application of rhBMP-7 as a

\* Corresponding author at: Orthopaedic Institute, G. Pini University of Milan, P.za Cardinal Ferrari, 1, Milan, Italy.  
Tel.: +39 02798809; fax: +39 02781233.

E-mail address: gmc@studiocalori.it (G.M. Calori).

bone-stimulating agent is superior compared to that of PRP with regard to their clinical and radiological efficacy.

© 2008 Elsevier Ltd. All rights reserved.

## Introduction

While the precise pathophysiology of bone repair failure at a cellular level remains largely undetermined, many of the factors that contribute to this failure are nowadays well recognised and understood.<sup>28,67</sup> These can be broadly categorised into general systemic factors<sup>25,44</sup> and local factors pertaining to the fracture site itself.<sup>2</sup> Subsequently, an effort to stimulate and augment the body's innate regenerative capabilities has been initiated.<sup>32</sup>

In this context, besides the undisputable superiority of autologous bone graft<sup>50,73</sup> and due to its limitations,<sup>5,45,60</sup> new adjuvant therapies have been implemented. Such alternatives, used either alone or in combination for the treatment of non-unions, are the use of electrical,<sup>15,51</sup> ultrasound,<sup>48</sup> and shockwave stimulation,<sup>3</sup> and a variety of bone graft substitutes with either osteoconductive or both osteoconductive and osteoinductive properties.<sup>3,15,20,23,33,48,51</sup>

The underlying rationale of all current cellular therapies, however, goes back to the seminal work of Urist,<sup>75</sup> who made the breakthrough discovery that intermolecular implantation of demineralised, lyophilised segments of allogeneic rabbit bone induces de novo formation of cartilage and bone.

This observation led to investigations culminating in the extensive purification of the osteoinductive activity of demineralised bone matrix (DBM) and the sequencing and cloning of the individual bone morphogenetic proteins (BMPs).<sup>80</sup>

BMPs are members of the transforming growth factor-beta (TGF- $\beta$ ) superfamily, and are characterised by immense osteoinductive potential. They induce a sequential cascade of events for chondroosteogenesis during bone formation and ultimately fracture healing, including chemotaxis,<sup>80</sup> proliferation of mesenchymal and osteoprogenitor cells,<sup>32</sup> and their differentiation into a chondrogenic or osteogenic lineage.<sup>36,71</sup>

Knowing the osteoinductive properties of BMPs and having identified their genetic sequences,<sup>66</sup> recombinant gene technology has been utilised to produce BMPs for clinical applications in the treatment of cases where bone regeneration is not anticipated, such as non-unions. Currently, recombinant BMP-2 and BMP-7 (in a collagen carrier) are used in a variety of complex orthopaedic conditions either as

adjuncts or as alternatives to conventional autologous bone grafting (ABG). Their efficacy has been shown to be favourably comparable to ABG and their use has been considered safe.<sup>16,27,39,40,43,56</sup>

As a result, the FDA issued a humanitarian device exemption for the application of rhBMP-7 as an alternative to autograft in recalcitrant long bone non-unions, in which the use of autograft is not feasible and alternative treatments have failed.<sup>41</sup>

Other means to enhance bone healing by use of autologous growth factors (AGFs) have also been instigated.

Platelet-rich plasma (PRP) is derived from autologous blood and is defined as a "certain volume of plasma that has a platelet concentration several-fold above the physiologic levels".<sup>69</sup> PRP elicits its actions via the degranulation of the alpha granules in platelets, which contain the synthesised and prepackaged growth factors.<sup>63</sup> The active secretion of these growth factors is initiated by the clotting process of blood. Growth factors released from the platelets include platelet-derived growth factor (PDGF), transforming growth factor (TGF beta 1 and beta 2), vascular endothelial growth factor (VEGF), epidermal growth factor (EGF), insulin-like growth factor 1 (IGF-1), and platelet factor 4 (PF4).<sup>63,77,81</sup> They also contain the three proteins in blood known to act as cell adhesion molecules for osteoconduction and as a matrix for bone, connective tissue, and epithelial migration; these cell adhesion molecules are fibrin itself, fibronectin, and vitronectin.<sup>63</sup>

The vast majority of published clinical studies regarding the application of PRP as a bone healing stimulator report a considerable acceleration of bone regeneration;<sup>10,19,30,53,57,63</sup> nonetheless, other authors have challenged these results.<sup>21,29,47</sup>

We conducted a prospective randomised trial in order to compare the clinical and radiological efficacy of rhBMP-7 and PRP in the treatment of persistent long bone non-unions not amenable to conventional therapeutic strategies.

## Patients and methods

Our study was conducted between April 2005 and July 2007 at the Orthopaedic Institute G. Pini (University of Milan) in cooperation with the Biomaterials Research Centre (C.R.S.B.) through

partial funding by the Administrative Department of Regione Lombardia.

Our goal was to compare the effectiveness and possible differences in the outcome of long bone non-union and osseous defects, reconstructive hip surgery and osteochondral defects, receiving treatment with rhBMP-7 or PRP. Only the results of the patient group with non-union defects will be discussed in this article.<sup>9</sup>

All our treatment protocols were approved by the Ethical Committee of Azienda Ospedaliera dell'Istituto Ortopedico Gaetano Pini.

### Inclusion and exclusion criteria

Patients with persistent long bone non-unions were randomised to two treatment groups (rhBMP-7 vs. PRP) based on a computer-generated randomisation list. The randomisation was developed to create two homogeneous groups.

The inclusion criteria were: post-traumatic atrophic non-union for at least 9 months, with no signs of healing over the last 3 months,<sup>46</sup> considered as non-treatable only by means of fixation revision.

Patients with one or more of the following criteria were excluded from our study: (i) skeletal immaturity, (ii) systemic infections or infected non-unions, (iii) insufficient skin to cover the fracture site and insufficient vascularisation at the non-union site, (iv) pathological fractures, (v) auto-immune/neoplastic active disorders, (vi) previous treatment with any growth factor, and (vii) need for autologous bone graft transplantation.

### Patient data documentation

We developed a specific computerised patient report form to record medical history, clinical and radiological data at baseline and during follow-up, which included: date of the initial injury, fracture classification according to AO<sup>70</sup> and Gustilo and Anderson,<sup>42</sup> the type and extent of bone defect in cm, soft tissue injuries, medical comorbidities, previous treatment with bone grafts (date and type of surgery), peri- and intra-operative clinical state, the presence of limb deformities (type, degree or cm of shortening), the presence of infection (ongoing, previous resolved) using the Cierny-Mader<sup>14</sup> classification, the applied treatment with either rhBMP-7 or PRP and any associated bone graft procedure (i.e. homologous, heterologous or synthetic bone, with the total exclusion of autologous bone grafts) systemic or local adverse events during and after surgery.

### Preparation of rhBMP-7, PRP, and bone grafts

The only rhBMP available in Italy is rhBMP-7 mixed with a bio-reabsorbable carrier (3.5 mg Eptotermin alpha, +1 g collagen, Osigraft®).<sup>26</sup> Prior to its application it was reconstituted with 2–3 ml of physiological solution.

Platelet-rich plasma was prepared according to a previously described method.<sup>63</sup> Briefly, aliquots of whole blood (54 or 108 ml) were collected in tubes containing acid-citrate-dextrose as an anti-coagulant (0.163 ml per 1 ml of blood) and centrifuged immediately after being drawn for 14 min, to separate red blood cells (RBCs) from platelets and plasma.

The supernatant composed of platelets and plasma was collected and centrifuged for a second time (14 min) in order to pellet the platelets, which were subsequently re-suspended in an appropriate volume of plasma, thus achieving the desired eight-fold platelet concentration above the normal blood levels, as confirmed by use of a counting chamber. We were thus able to obtain 20 ml of PRP.

The bone substitutes used in our study were homologous bone, xenografts and synthetic bone composites (hydroxyapatite). Homologous bone preserved from our bone bank was used in order to fill larger segment gaps. Once defrosted in physiological solution at 40 °C, the bone allografts were used depending on surgical needs, either morcelised (with grinding tools or manually) in order to obtain bone chips varying from 0.5 to 1 cm in size, or grafted as a whole, after congruence adaptation. Xenografts and synthetic bone substitutes (hydroxyapatite) were used mainly as fillers for small bone defects.

### Study protocol

Following the randomised assignment to either the rhBMP-7 or the PRP treatment group, each patient underwent non-emergency operation for the treatment of their atrophic non-union, where adjuvant bone grafts were used according to the surgeon's choice. Revision of fixation method was implemented when deemed necessary.

In this study, 10 surgeons from three different units participated. They attended a preliminary meeting to clarify the protocol, the aim of this study and to share the guidelines in order to make the valuation homogeneous.

The postoperative rehabilitation protocol included initial splint immobilisation for the upper extremity fractures, subsequently followed by progressive mobilisation depending on the clinical and

radiological assessment. For the lower extremity fractures, initial toe touch weight bearing using crutches was encouraged, progressing to full-weight bearing when deemed appropriate.

Clinical and radiological evaluations were carried out pre-operatively, intra-operatively, before hospital discharge and postoperatively (at 1, 3, 6, 9 and 12 months or longer where needed).

The radiographs were reviewed by one radiologist and two surgeons previously trained and instructed about the protocol of the study.

Following discharge from the hospital, all patients were followed up for at least 9 months, a time frame which was set as the primary end-point of our study. Successful completion of treatment was defined as the accomplishment of both clinical and radiological union. Clinical union was regarded as pain-free full-weight bearing for lower extremity fracture non-unions, and pain-free movement for fracture non-unions of the upper extremity. Successful radiological union was judged by the presence and staging of callus at 3/4 cortices on both anteroposterior (AP) and lateral views, as well as the type of osteointegration.

Perioperative and postoperative complications were recorded and classified as severe (potentially life threatening and requiring treatment), moderate (non-life threatening but requiring therapeutic intervention), or mild (resolved without any treatment). All adverse events were classified as serious or non-serious according to the International Conference of Harmonization (ICH) Guidelines.<sup>46</sup>

Adverse effects occurring during the operation, immediately after the operation, or at a later stage were recorded through a prospective protocol of serially collected blood samples.

Functional outcome in terms of presence or absence of pain was assessed during the postopera-

tive follow-up period by use of a modified Visual Analogue Score<sup>72</sup> scaled from one to ten. Results were recorded as pain-free movement with or without weight bearing.

## Statistics

All statistical analyses of the data were performed with SPSS (version 13.0, SPSS software Chicago, Illinois) using the  $\chi^2$ -test with an arbitrary distribution, and *p*-values of <0.05 were considered significant.

## Results

All patients completed at least the 9-month follow-up period. Out of 120 patients (120 non-unions) that were prospectively enrolled, 60 were allocated to the rhBMP-7 and 60 to the PRP treatment group. The demographics of the study groups are presented in Table 1. Our two randomly assigned populations were similar in most respects, including age, gender, closed/open fracture ratio, duration of non-union, and the number of prior surgical interventions.

The power of this study with a confidence level set at 5% was 78.5%. The patients recruited had a median age of 44 years (range 19–65) in the group treated with rhBMP-7 and of 41 (range 21–62) years in the group treated with PRP (*p* = 0.0754 not significant).

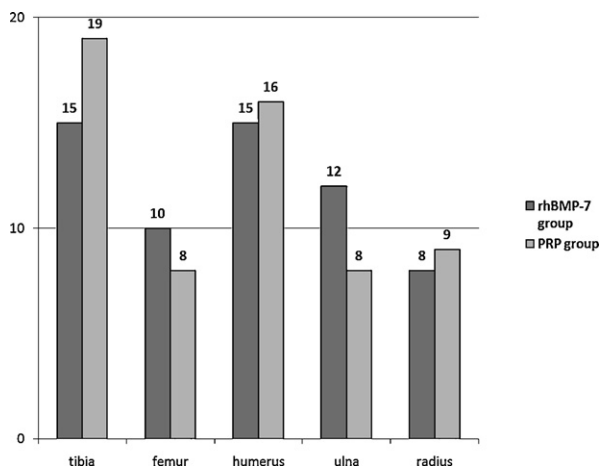
In the rhBMP-7 group there were 15 tibial non-unions, 10 femoral, 15 humeral, 12 ulnar, and 8 radial non-unions. In the PRP group there were 19 tibial non-unions, 8 femoral, 16 humeral, 8 ulnar, and 9 radial non-unions (Fig. 1).

In the atrophic non-union there was a bone loss that needed a scaffold to correct the deformity. This

**Table 1** Demographics of patient population

	rhBMP-7		PRP	
Number of patients	60		60	
Gender (male/female)	32/28		35/25	
Age (years, median + range)	44 (19–65)*		41 (21–62)*	
Nicotine use %	33.3		28.3	
Open fracture at injury	4	1 Grade II 2 Grade IIIa 1 Grade IIIb	5	1 Grade I 1 Grade II 2 Grade IIIa 1 Grade IIIb
Duration of non-union (months, median ± S.D.)	20.2 ± 2.35		19.2 ± 2.86	
Number of previous surgeries (median + range)	2 (1–5)		2 (1–5)	
Prior autograft implementation	23/60 (38.3%)		21/60 (35%)	

\* *p* = 0.0754 not significant.



**Figure 1** Anatomical distribution of the clinical application of rhBMP-7 and PRP.

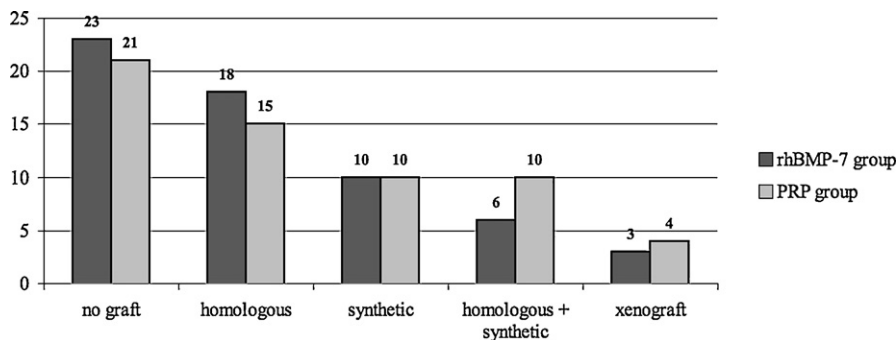
gap was classified into three groups—Group A: gap <1 cm. Group B: gap from 1 to 3 cm. Group C: gap >3 cm.

Group A = 55 patients (45.83%), Group B = 47 patients (39.16%), Group C = 18 patients (15.0%).

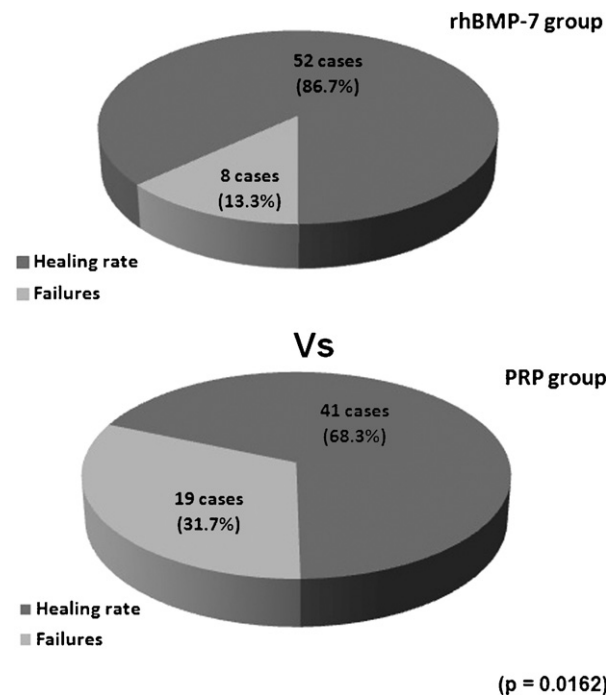
Prior to our intervention, a median non-union duration of  $20.2 \pm 1.34$  months and of  $19.4 \pm 1.45$  months with a median number of previous surgeries of 2 (range 1–5) and of 2 (range 1–5) was documented in the groups treated with rhBMP-7 and PRP, respectively. In an attempt to promote fracture healing, 23/60 (38.3%) patients and 21/60 (35%) patients of the rhBMP-7 and the PRP group respectively were previously additionally treated with autografts (Table 1).

During our intervention, the application of the growth factors in 40/60 (66.6%) and 48/60 (80%) of rhBMP-7 and PRP patients respectively was complemented by a revision of their fracture fixation ( $p = 0.0986$ ) (Table 2). Furthermore, bone grafts were used in 37/60 cases in the rhBMP-7 group and in 39/60 cases in the PRP group (Fig. 2) ( $p = 0.1$ ).

The bone grafts were used when the surgeon had evidence that the correction of the deformity



**Figure 2** Types of bone grafts used.



**Figure 3** Clinical and radiological healing and failure rates.

needed a scaffold as a support for the non-union healing.

One vial of rhBMP-7 was used in 58/60 patients of the rhBMP-7 group and two vials in the remaining two patients. We decided to use two vials because in these two cases there was a high osseous volume, so to maintain the right concentration of BMP-7 in the osteointegrative interface, we needed a higher dose. In the PRP group the amount of PRP used was 20 ml or slightly less based upon the size of the long bone defect resulting from the excision of the fibrous tissue.

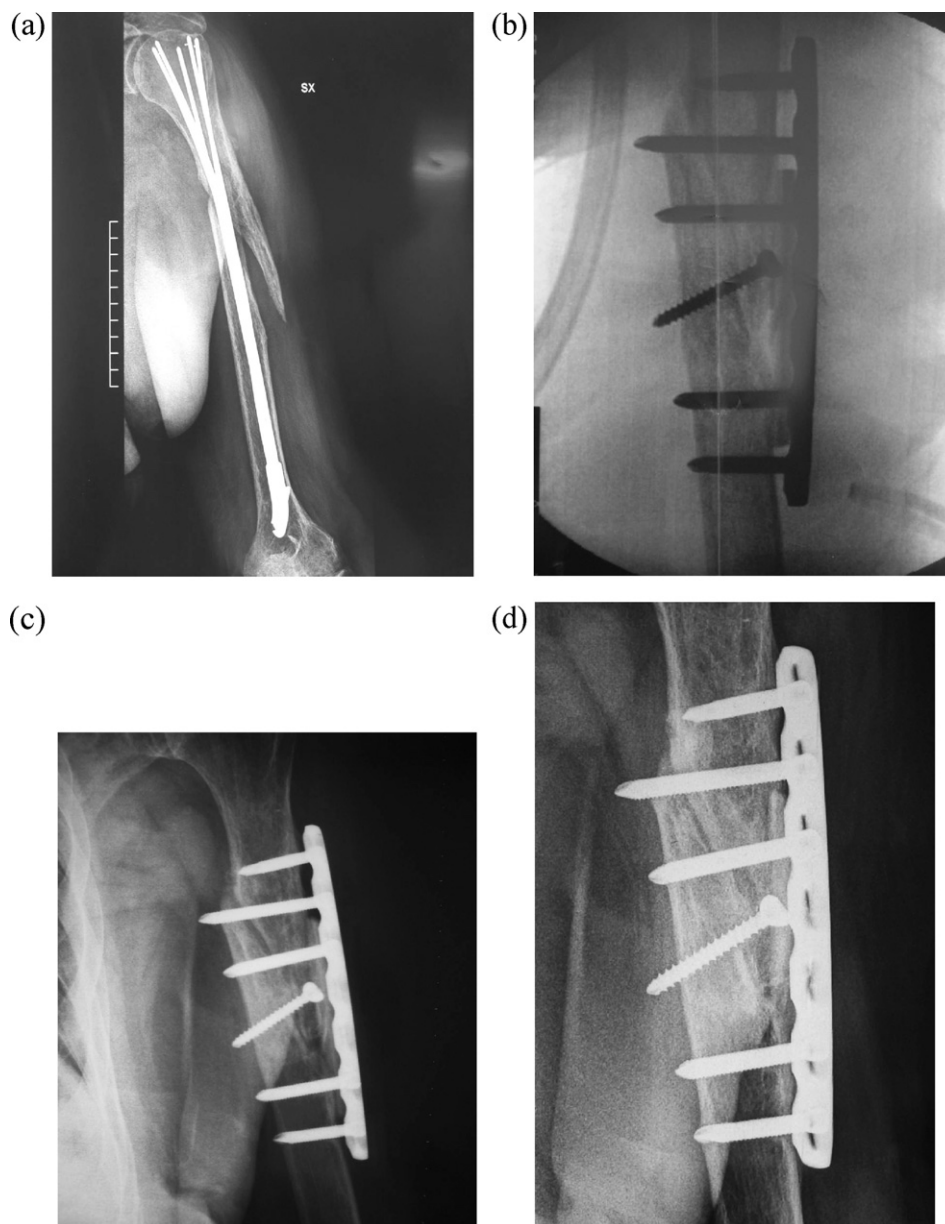
**Study outcomes**

Overall, 52/60 non-unions (86.7%) treated with rhBMP-7 and 41/60 (68.3%) non-unions treated with PRP progressed to clinical and radiological union

**Table 2** Summary of fixation treatment per study group

Non-union site	rhBMP-7 group					PRP group				
	n	Fixation treatment prior to our intervention		Fixation revision during our intervention	Summary of fixation treatment	n	Fixation treatment prior to our intervention		Fixation revision during our intervention	Summary of fixation treatment
		Initial fixation after injury (preserved during our intervention)	Fixation revision after non-union				Initial fixation after injury (preserved during our intervention)	Fixation revision after non-union		
Tibia	15	1 IMN, 2 ORIF, 1 EF	2 IMN, 2 ORIF 2 IMN, 4 ORIF 1 IMN	4 IMN 6 ORIF 1 EF	5 IMN, 8 ORIF, 2 EF	19	2 IMN, 2ORIF, 1 EF	3 IMN, 2 ORIF 2 IMN, 6 ORIF 1 EF	5 IMN 8 ORIF 1 EF	7 IMN, 10 ORIF, 2 EF
Femur	10	2 IMN, 1 EF	1 EF, 2 IMN 4 ORIF	3 IMN 4 ORIF	5 IMN, 4 ORIF, 1 EF	8	1 IMN	1 IMN, 1 EF 3 ORIF 2 ORIF	2 IMN 3 ORIF 2 EF	3 IMN, 3 ORIF, 2 EF
Humerus	15	2 IMN, 3 ORIF, 1 EF	2 IMN 3 ORIF, 1 EF, 1 IMN 2 EF	2 IMN 5 ORIF 2 EF	4 IMN, 8 ORIF, 3 EF	16	1 IMN, 1 ORIF, 1 EF	3 IMN 2 IMN, 4 ORIF 2 ORIF, 3 EF	3 IMN 6 ORIF 4 EF	4 IMN, 7 ORIF, 5 EF
Ulna	12	4 ORIF, 1 EF	3 ORIF, 2 K-W, 1 IMN 1 EF	6 ORIF 1 EF	10 ORIF, 2 EF	8	2 ORIF	2 ORIF, 1 K-W 1 ORIF, 1 EF	4 ORIF 2 EF	6 ORIF, 2 EF
Radius	8	1 ORIF, 1 EF	3 ORIF, 2 K-W 1 EF	5 ORIF 1 EF	7 ORIF, 1 EF	9	1 ORIF	4 ORIF, 2 K-W 1 ORIF, 1 EF	6 ORIF 2 EF	7 ORIF, 2 EF

ORIF (open reduction internal fixation), EF (external fixator), IM (reamed intramedullary nailing).



**Figure 4** Case presentation (rhBMP-7 group). (a) Female, 78 year old, diaphyseal humerus fracture (AO: 12 B1), treated with Marchetti nail. Implant failure resulting to atrophic non-union. (b) Intra-operative X-ray: fixation revision + implantation of AO L.C.P. + lyophilised allograft + one vial rhBMP-7. (c) 3 months postoperative X-ray—clinical evaluation: no pain, ROM: reduced. Radiographic evaluation: formation of initial bone bridging. (d) 7 months postoperative X-ray—clinical evaluation: no pain, ROM: complete. Radiographic evaluation: adequate callus formation.

( $p = 0.016$ ) (Fig. 3). Both the median clinical and radiographic healing time were lower in the rhBMP-7 group compared to the PRP group ( $3.5 \pm 0.48$  months vs.  $4 \pm 0.61$  months and  $8 \pm 0.48$  months vs.  $9 \pm 0.52$  months, respectively).

The mean follow up time was 12.43 months (range 9–25 months).

In eight cases we had no clear evidence of fracture healing and we performed a CT scan to clarify the results of the surgery.

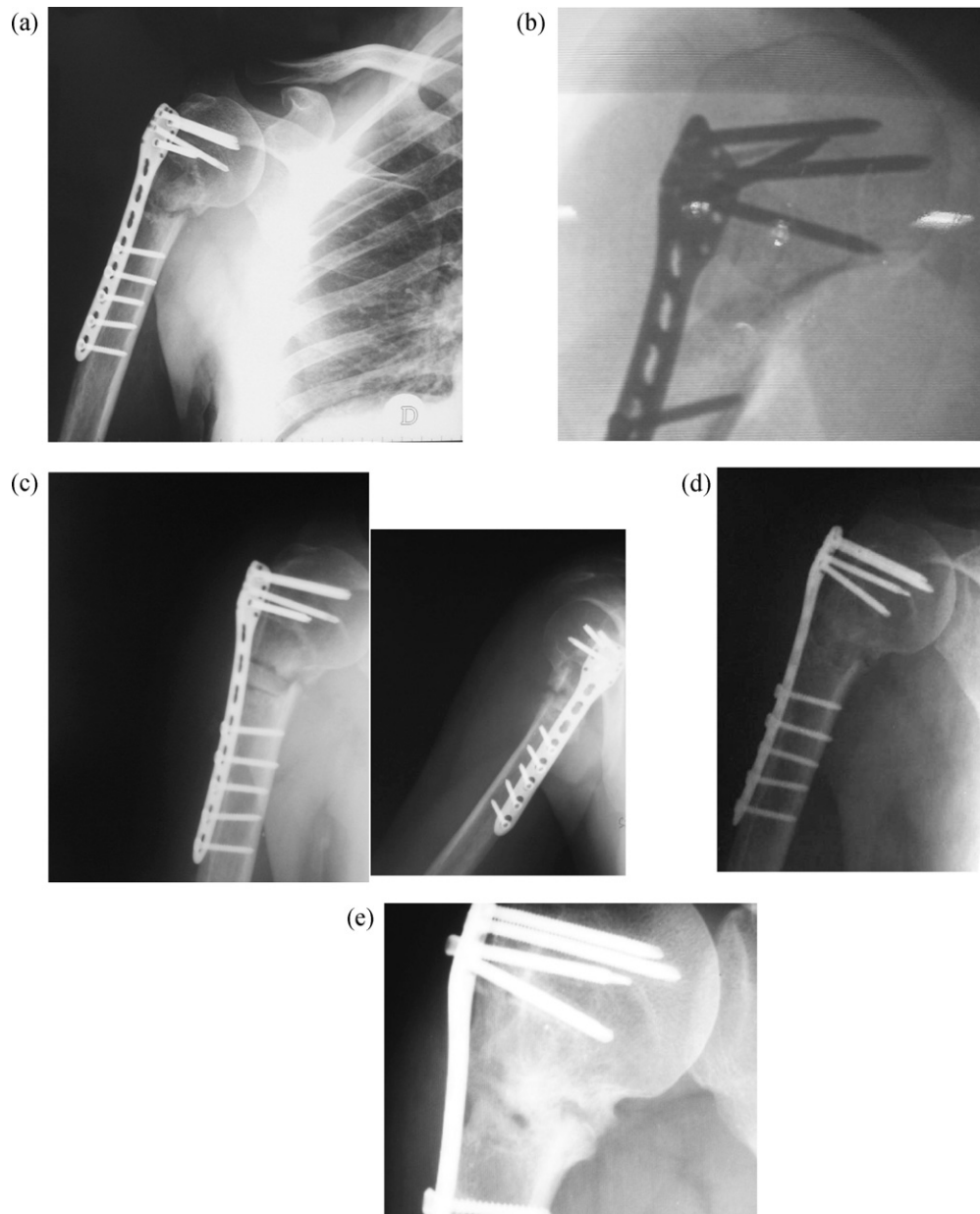
**Table 3** Infections' classification per group

Classification <sup>14</sup> of infection cases per group	
rhBMP-7	PRP
1 II Bl	1 III A
1 III Bl	2 II Bl
2 II Bs	1 III Bl
	1 III Bls

Four non-unions in the rhBMP-7 group and five non-unions in the PRP group were complicated by infection and despite adjuvant treatment they failed to progress to union (Table 3).

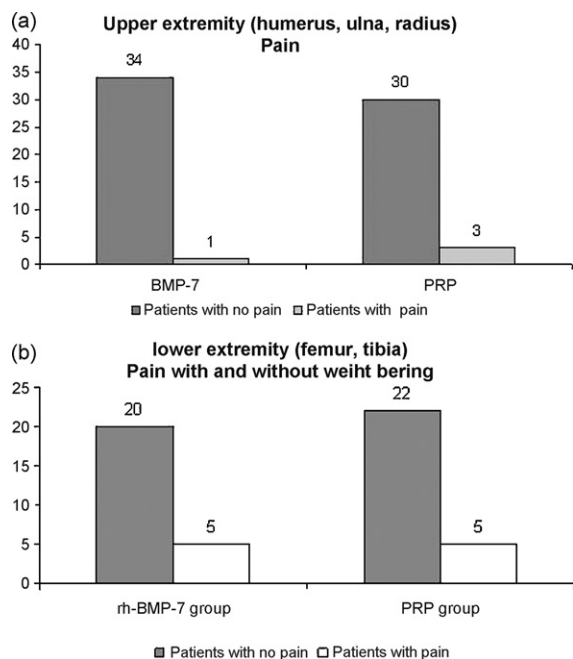
For the remaining three cases of the rhBMP-7 group and the thirteen cases of the PRP group, a re-intervention procedure was deemed necessary ( $p = 0.0317$ ). In the rhBMP-7 group one patient sustained a refracture due to a fall and two patients presented with no radiologically visible

callus formation (Figs. 4 and 5). In the PRP group one patient sustained a refracture due to severe osteopenia. Radiologically, in nine cases there was no callus formation and in the remaining three patients poor callus formation was observed. However, despite these additional fixation revisions, union was not achieved. Finally, one patient out of each group has not yet received any further treatment for their persistent non-union following our intervention.



**Figure 5** Case presentation (rhBMP-7 group). (a) Male, 64 year old, ISS > 8, proximal humerus fracture (AO: 11 A2), treated with PH-LCP, ISS > 8. Atrophic non-union. (b) Intra-operative X-ray: intervention: allograft + 1 vial of rhBMP-7, without fixation revision. No adverse events encountered. (c) 1 month postoperative X-ray—clinical evaluation: no pain, ROM: complete. Radiographic evaluation: poor callus formation. (d) 3 months postoperative X-ray—clinical evaluation: no pain, ROM: complete. RX: initial bone bridging. (e) After 6 months—clinical evaluation: no pain, ROM: complete. RX: no progression of callus, initial allograft failure.





**Figure 6** (a and b) Prevalence of pain in upper and lower extremity fractures.

Pain-free movement was reported by all of 35 patients with upper extremity fractures treated with rhBMP-7 at our nine month primary end point, compared to 30 out of 33 patients treated with PRP who had a satisfactory functional outcome. The percentage of reported pain with and without weight bearing in patients with lower extremity fractures treated with either rhBMP-7 or PRP was similar in both groups<sup>72</sup> (Fig. 6a and b).

## Discussion

With the developments made in the field of molecular biology and genetics, much attention has been recently placed on the healing environment at the molecular level.<sup>24,34</sup> Despite the often contradicting evidence regarding the exact pathophysiology of bone repair failure,<sup>4,8,58,68</sup> a complete understanding of this cellular process is becoming closer,<sup>52</sup> and manipulation of the local fracture environment by application of growth factors has been considered a treatment option from which positive results have been reported.<sup>37,38,54,55,60,64,79</sup>

RhBMP-7, by virtue of its inherent osteoinductive properties,<sup>55</sup> has been used as a biological inducer for the enhancement of bone regeneration in various clinical applications including persistent non-unions.<sup>17,23,31,76,79</sup>

The seminal work of Friedlaender et al.<sup>27</sup> has been a remarkable example of clinical translation

illustrating the integration of the developed recombinant BMP-7 technology in the clinical setting. The authors conducted a multicentre, prospective, randomised trial comparing the efficacy of OP-1 (3.5 mg of rhBMP-7 in a bovine bone derived type-1 collagen-particle delivery vehicle; Stryker Biotech, Hopkinton, Massachusetts) with that of autografting in the treatment of 122 patients with a total of 124 tibial non-unions. As statistical analysis of these results showed equivalent efficacy between OP-1 and autograft, the authors concluded that OP-1 was a safe and effective alternative to bone graft in the treatment of tibial non-unions.<sup>27</sup>

The purpose of this study was to compare the results of rhBMP-7 and PRP in the treatment of persistent long bone non-unions with regard to their clinical and radiological efficacy. An overall 86.7% successful clinical and radiological healing rate in the group of patients treated with rhBMP-7 was found, compared to 68.3% of successful treatment occurred in the PRP treated patient group. Furthermore, a lower median radiographic healing time in the rhBMP-7 group (8 months vs. 9 months in PRP group) and a lower median clinical healing time in the rhBMP-7 group (3.5 months vs. 4 months in PRP group) were seen.

These results compare favourably to those published not only by Friedlaender et al.<sup>27</sup> but by other authors as well.<sup>6,22,31,38,61</sup> As we implemented various fixation techniques, our study does not suffer from the limitation in the study by Friedlaender et al.,<sup>27</sup> who could not control for the potential healing effects produced by reamed intramedullary nailing of tibial non-unions.<sup>50</sup>

The superior results found in our rhBMP-7 group could be justified in view of its expression in the complex intra- and extracellular signaling process.<sup>12</sup>

BMPs, together with other cytokines and matrix components, induce a cascade of cellular events necessary for bone repair. They initiate endochondral bone formation by inducing mesenchymal stem cells to differentiate into osteoblasts and to produce new bone tissue.<sup>59,80</sup> Furthermore, they enhance bone collagen synthesis, i.e., BMP stimulates adjacent bone cells to grow into, and eventually replace, the collagen scaffold, which is then resorbed.<sup>7,55</sup> Apart from that, BMPs appear to be the most selective for osteogenesis, and have the greatest effect upon it.<sup>12</sup>

On the other hand, the rationale for the local application of PRP in bone surgery is the release of growth factors that appear/exist in the platelets. In spite of the *in vitro* observed mitogenic effects of PRP on osteoblast-like cells,<sup>78</sup> the actions of these growth factors are very complex, because each growth factor may have a different effect on

the same tissues, as well as different responses that are dependent on specific tissues.<sup>11</sup> Moreover, differences in preparation techniques noted even in FDA approved products<sup>69</sup> may have an impact on the expression of those autologous growth factors.<sup>1</sup>

In our study, the failure rate recorded in the rhBMP-7 treatment group was significantly lower compared to the one observed in the PRP group. In addition, the radiographic analysis of these cases revealed differences with regard to the quality or the absence of callus formation at our primary time end-point, which were statistically significant in our two treatment groups. Studies histomorphometrically evaluating the enhancement of bone healing by use of platelet-rich plasma (PRP) on early and late stages<sup>74</sup> showed that PRP may influence the early phase of bone healing, but elicits a rather low regenerative capacity after 6 months of administration. These findings in combination with the "direct" inherent osteoinductive properties of rhBMP-7 could be responsible for the differences observed in our study population.

Concerns regarding the safety of exogenous administered growth factors have been raised recently, based on published evidence supporting transient adverse effects related to the administration of rhBMP-7.<sup>43</sup> On the contrary, platelet-rich plasma, due to its autogenous preparation, is considered inherently safe, provided that an aseptic technique is followed.<sup>62</sup> In both our study populations, adverse effects that could be attributed to the use of the growth factors were not encountered. Infection encountered in both our treatment groups could be attributed to the application of the growth factors as well. However, as we did not perform immunological studies, a fact that could be regarded as a limitation of our study, we are not able to present sound evidence supporting this view.

Another limitation of our study was the fact that we did not prospectively control for outcome differences regarding the impregnation of rhBMP-7 and PRP into various bone grafts. It has been shown that different bone substitutes affect the concentration of growth factors in PRP.<sup>13</sup> However, in both of our treatment groups we did not record any results in favour of a specific implemented combination.

In the broadened context of the Diamond Concept as it was introduced by Giannoudis et al.,<sup>35</sup> our comparable outcome results of both groups, concerning the lower extremity treated fractures, prompt us/lead us to hypothesise that the role of mechanical stability in bone regeneration is far more important than we have considered so far, especially in load bearing environments. This assumption is further supported by the rhBMP-7

favourable outcome results recorder in patients who had sustained upper extremity fractures. However, the small number of cases treated with different fixation techniques in both our groups does not allow for statistical interpretation of the effect of mechanical stability on the elucidation of growth factors' actions.

In the era of regenerative medicine, the paradigm change in our concept of "biocompatibility", from the absence of cytotoxicity to the demand for biofunctionality and reproducibility, is accompanied by the need for cost justification of the various therapies.<sup>18,49,65</sup> In this view, the findings of our study regarding the time elapsed prior to our interventions, the percentage of successful healing rates observed in the rhBMP-7 group and the significantly lower rate of re-interventions recorded in that group support the cost-effectiveness of the clinical translation of the highly sophisticated BMP-7 recombinant technology.

It is noteworthy that our results regarding the administration of PRP do not share the enthusiasm reflected in recent publications regarding its application in the clinical setting.<sup>19,53,57</sup> However, a critical literature review will easily show pivotal differences with our study which mainly comprise the amplification of PRP's actions through a combined application of PRP either with autologous bone grafts<sup>57</sup> or bone marrow stromal cells.<sup>19</sup> In our group of patients, PRP was administered alone, impregnated in various types of bone substitutes, with the exception of autologous bone graft; a strategy which could be perceived as non-ideal in terms of exploiting PRP's innate bone regeneration enhancement capabilities.

## Conclusion

Despite the ongoing developments of new strategies or the improvement of the existing ones for the treatment of fracture non-unions, their management remains difficult. In the daily clinical environment, many orthopaedic surgeons are still sceptical about the current levels of evidence supporting the use of biological response modifiers. Based on the results of our prospective randomised clinical study, we conclude in favour of the use of rhBMP-7 in the treatment of persistent long bone non-unions compared to PRP in terms of clinical and radiological efficacy. Further challenges regarding the complete characterisation of the platelet released growth factors and proteins, on the one hand, and the optimisation of their preparation and delivery techniques, on the other, still need to be addressed. In the quest of "bench to bedside" applications, the

use of the existing BMP-7 recombinant technology has proven its superiority and reproducibility. Additional studies comparing the differences of intra-individual biological responses observed in recently emerged cell-based and autologous growth factor therapies are warranted.

## Conflict of interest

None.

## References

- Anitua E, Sanchez M, Nurden AT, et al. New insights into and novel applications for platelet-rich fibrin therapies. *Trends Biotechnol* 2006;24:227–34.
- Aspenberg P, Basic N, Tagil M, Vukicevic S. Reduced expression of BMP-3 due to mechanical loading: a link between mechanical stimuli and tissue differentiation. *Acta Orthop Scand* 2000;71:558–62.
- Bara T, Synder M. Nine-years experience with the use of shock waves for treatment of bone union disturbances. *Ortop Traumatol Rehabil* 2007;9:254–8.
- Bhandari M, Guyatt GH, Swiontkowski MF, et al. A lack of consensus in the assessment of fracture healing among orthopaedic surgeons. *J Orthop Trauma* 2002;16:562–6.
- Bimmel R, Govaers K. Does harvesting of iliac bone grafts with an acetabular reamer reduce complication rate? *Acta Orthop Belg* 2006;72:598–602.
- Bong MR, Capla EL, Egol KA, et al. Osteogenic protein-1 (bone morphogenetic protein-7) combined with various adjuncts in the treatment of humeral diaphyseal nonunions. *Bull Hosp Joint Dis* 2005;63:20–3.
- Bostrom MP, Lane JM, Berberian WS, et al. Immunolocalization and expression of bone morphogenetic proteins 2 and 4 in fracture healing. *J Orthop Res* 1995;13:357–67.
- Brownlow HC, Reed A, Simpson AH. The vascularity of atrophic non-unions. *Injury* 2002;33:145–50.
- Calori GM, D'Avino M, Tagliabue L, et al. An ongoing research for evaluation of treatment with BMPs or AGFs in long bone non-union: protocol description and preliminary results. *Injury* 2006;37(Suppl. 3):S43–50.
- Camargo PM, Lekovic V, Weinlaender M, et al. Platelet-rich plasma and bovine porous bone mineral combined with guided tissue regeneration in the treatment of intrabony defects in humans. *J Periodontal Res* 2002;37:300–6.
- Carlson ER. Bone grafting the jaws in the 21st century: the use of platelet-rich plasma and bone morphogenetic protein. *Alpha Omegan* 2000;93:26–30.
- Cheng H, Jiang W, Phillips FM, et al. Osteogenic activity of the fourteen types of human bone morphogenetic proteins (BMPs). *J Bone Joint Surg Am* 2003;85-A:1544–52.
- Cho HS, Park SY, Kim S, et al. Effect of different bone substitutes on the concentration of growth factors in platelet-rich plasma. *J Biomater Appl* 2008.
- Ciorny III G, Mader JT, Penninck JJ. A clinical staging system for adult osteomyelitis. *Clin Orthop Relat Res* 2003;414:7–24.
- Ciombor DM, Aaron RK. The role of electrical stimulation in bone repair. *Foot Ankle Clin* 2005;10:579–93. vii.
- Cook SD, Barrack RL, Patron LP, Salkeld SL. Osteogenic protein-1 in knee arthritis and arthroplasty. *Clin Orthop Relat Res* 2004;140–5.
- Crowley DJ, Kanakaris NK, Giannoudis PV. Femoral diaphyseal aseptic non-unions: is there an ideal method of treatment? *Injury* 2007;38(Suppl. 2):S55–63.
- Dahabreh Z, Dimitriou R, Giannoudis PV. Health economics: a cost analysis of treatment of persistent fracture non-unions using bone morphogenetic protein-7. *Injury* 2007;38:371–7.
- Dallari D, Savarino L, Stagni C, et al. Enhanced tibial osteotomy healing with use of bone grafts supplemented with platelet gel or platelet gel and bone marrow stromal cells. *J Bone Joint Surg Am* 2007;89:2413–20.
- De Long Jr WG, Einhorn TA, Koval K, et al. Bone grafts and bone graft substitutes in orthopaedic trauma surgery: a critical analysis. *J Bone Joint Surg Am* 2007;89:649–58.
- de Vasconcelos Gurgel BC, Goncalves PF, Pimentel SP, et al. Platelet-rich plasma may not provide any additional effect when associated with guided bone regeneration around dental implants in dogs. *Clin Oral Implants Res* 2007;18:649–54.
- Dimitriou R, Dahabreh Z, Katsoulis E, et al. Application of recombinant BMP-7 on persistent upper and lower limb non-unions. *Injury* 2005;36(Suppl. 4):S51–9.
- Dinopoulos H, Giannoudis PV. (iv) The use of bone morphogenetic proteins (BMPs) in long-bone non-unions. *Curr Orthopaed* 2007;21:268–79.
- Einhorn TA. Enhancement of fracture healing. *Instr Course Lect* 1996;45:401–16.
- Einhorn TA, Bonnarens F, Burstein AH. The contributions of dietary protein and mineral to the healing of experimental fractures: a biomechanical study. *J Bone Joint Surg Am* 1986;68:1389–95.
- EMEA European public assessment report. procedure: no. EMEA/H/C/293; 2000.
- Friedlaender GE, Perry CR, Cole JD, et al. Osteogenic protein-1 (bone morphogenetic protein-7) in the treatment of tibial nonunions. *J Bone Joint Surg Am* 2001;83-A(Suppl. 1):S151–8.
- Frölke JPM, Patka P. Definition and classification of fracture non-unions. *Injury* 2007;38(Suppl. 2):S19–22.
- Froom SJ, Wallace SS, Tarnow DP, Cho SC. Effect of platelet-rich plasma on bone growth and osseointegration in human maxillary sinus grafts: three bilateral case reports. *Int J Periodon Rest Dent* 2002;22:45–53.
- Garg AK. The use of platelet-rich plasma to enhance the success of bone grafts around dental implants. *Dent Implantol Update* 2000;11:17–21.
- Geesink RG, Hoefnagels NH, Bulstra SK. Osteogenic activity of OP-1 bone morphogenetic protein (BMP-7) in a human fibular defect. *J Bone Joint Surg Br* 1999;81:710–8.
- Gerstenfeld LC, Cullinane DM, Barnes GL, et al. Fracture healing as a post-natal developmental process: molecular, spatial, and temporal aspects of its regulation. *J Cell Biochem* 2003;88:873–84.
- Giannoudis PV, Dinopoulos H, Tsiroidis E. Bone substitutes: an update. *Injury* 2005;36(Suppl. 3):S20–7.
- Giannoudis PV, Einhorn TA, Marsh D. Fracture healing: a harmony of optimal biology and optimal fixation? *Injury* 2007;38(Suppl. 4):S1–2.
- Giannoudis PV, Einhorn TA, Marsh D. Fracture healing: the diamond concept. *Injury* 2007;38(Suppl. 4):S3–6.
- Giannoudis PV, Kanakaris NK, Einhorn TA. Interaction of bone morphogenetic proteins with cells of the osteoclast lineage: review of the existing evidence. *Osteoporos Int* 2007;18:1565–81.
- Giannoudis PV, Psarakis S, Kanakaris NK, Pape HC. Biological enhancement of bone healing with bone morphogenetic protein-7 at the clinical setting of pelvic girdle non-unions. *Injury* 2007;38(Suppl. 4):S43–8.
- Giannoudis PV, Tzioupis C. Clinical applications of BMP-7: the UK perspective. *Injury* 2005;36(Suppl. 3):S47–50.

39. Govender S, Csimma C, Genant HK, et al. Recombinant human bone morphogenetic protein-2 for treatment of open tibial fractures: a prospective, controlled, randomized study of four hundred and fifty patients. *J Bone Joint Surg Am* 2002;84-A:2123–34.
40. Grauer JN, Patel TC, Erulkar JS, et al. Young Investigator Research Award winner. Evaluation of OP-1 as a graft substitute for intertransverse process lumbar fusion. *Spine* 2001;26:127–33.
41. Guidance document for the preparation of investigational device exemptions and pre-market approval applications for bone growth stimulator devices. Rockville, MD: United States Food and Drug Administration; 1988.
42. Gustilo RB, Anderson JT. Prevention of infection in the treatment of one thousand and twenty-five open fractures of long bones: retrospective and prospective analyses. *J Bone Joint Surg Am* 1976;58:453–8.
43. Harwood PJ, Giannoudis PV. Application of bone morphogenetic proteins in orthopaedic practice: their efficacy and side effects. *Expert Opin Drug Saf* 2005;4:75–89.
44. Hayda RA, Brighton CT, Esterhai Jr JL. Pathophysiology of delayed healing. *Clin Orthop Relat Res* 1998;351:40.
45. Hierholzer C, Sama D, Toro JB, et al. Plate fixation of ununited humeral shaft fractures: effect of type of bone graft on healing. *J Bone Joint Surg Am* 2006;88:1442–7.
46. International conference of harmonization guideline clinical safety data management: definitions and standards for expedited reporting. Federal Register, March 1, 1995.
47. Jensen TB, Rahbek O, Overgaard S, Soballe K. Platelet rich plasma and fresh frozen bone allograft as enhancement of implant fixation. an experimental study in dogs. *J Orthop Res* 2004;22:653–8.
48. Jingushi S, Mizuno K, Matsushita T, Itoman M. Low-intensity pulsed ultrasound treatment for postoperative delayed union or nonunion of long bone fractures. *J Orthop Sci* 2007;12:35–41.
49. Kanakaris NK, Giannoudis PV. The health economics of the treatment of long-bone non-unions. *Injury* 2007;38(Suppl. 2):S77–84.
50. Kanakaris NK, Paliobeis C, Manidakis N, Giannoudis PV. Biological enhancement of tibial diaphyseal aseptic non-unions—the efficacy of autologous bone grafting: BMPs and reaming by-products. *Injury* 2007;38(Suppl. 2):S65–75.
51. Karamitros AE, Kalentzos VN, Soucacos PN. Electric stimulation and hyperbaric oxygen therapy in the treatment of nonunions. *Injury* 2006;37(Suppl. 1):S63–73.
52. Khan SN, Bostrom MP, Lane JM. Bone growth factors. *Orthop Clin North Am* 2000;31:375–88.
53. Kitoh H, Kitakoji T, Tsuchiya H, et al. Transplantation of marrow-derived mesenchymal stem cells and platelet-rich plasma during distraction osteogenesis—a preliminary result of three cases. *Bone* 2004;35:892–8.
54. Kontakis GM, Papadokostakis GM, Alpantaki K, et al. Intramedullary nailing for non-union of the humeral diaphysis: a review. *Injury* 2006;37:953–60.
55. Lane JM. Bone morphogenetic protein science and studies. *J Orthop Trauma* 2005;19:S17–22.
56. Lieberman JR, Conduah A, Urist MR. Treatment of osteonecrosis of the femoral head with core decompression and human bone morphogenetic protein. *Clin Orthop Relat Res* 2004;139–45.
57. Lowery GL, Kulkarni S, Pennisi AE. Use of autologous growth factors in lumbar spinal fusion. *Bone* 1999;25:475–505.
58. Lu C, Miclau T, Hu D, Marcucio RS. Ischemia leads to delayed union during fracture healing: a mouse model. *J Orthop Res* 2007;25:51–61.
59. Maegawa N, Kawamura K, Hirose M, et al. Enhancement of osteoblastic differentiation of mesenchymal stromal cells cultured by selective combination of bone morphogenetic protein-2 (BMP-2) and fibroblast growth factor-2 (FGF-2). *J Tissue Eng Regen Med* 2007;1:306–13.
60. Mahendra A, Maclean AD. Available biological treatments for complex non-unions. *Injury* 2007;38(Suppl. 4):S7–12.
61. Maniscalco P, Gambera D, Bertone C, et al. Healing of fresh tibial fractures with OP-1: a preliminary report. *Acta Biomed* 2002;73:27–33.
62. Marx RE. Platelet-rich plasma: evidence to support its use. *J Oral Maxillofac Surg* 2004;62:489–96.
63. Marx RE, Carlson ER, Eichstaedt RM, et al. Platelet-rich plasma: growth factor enhancement for bone grafts. *Oral Surg Oral Med Oral Pathol Oral Radiol Endod* 1998;85:638–46.
64. McKee MD. Recombinant human bone morphogenetic protein-7: applications for clinical trauma. *J Orthop Trauma* 2005;19:S26–8.
65. Olson S, Hahn D. Surgical treatment of non-unions: a case for internal fixation. *Injury* 2006;37:681–90.
66. Ozkaynak E, Rueger DC, Drier EA, et al. OP-1 cDNA encodes an osteogenic protein in the TGF-beta family. *EMBO J* 1990;9:2085–93.
67. Poynton AR, Lane JM. Safety profile for the clinical use of bone morphogenetic proteins in the spine. *Spine* 2002;27:S40–8.
68. Reed AA, Joyner CJ, Brownlow HC, Simpson AH. Human atrophic fracture non-unions are not avascular. *J Orthop Res* 2002;20:593–9.
69. Roukis TS, Zgonis T, Tiernan B. Autologous platelet-rich plasma for wound and osseous healing: a review of the literature and commercially available products. *Adv Ther* 2006;23:218–37.
70. Rüedi TP, Murphy WM. Principles of fracture management. Stuttgart: Thieme; 2000.
71. Sakou T. Bone morphogenetic proteins: from basic studies to clinical approaches. *Bone* 1998;22:591–603.
72. Scott J, Huskisson EC. Graphic representation of pain. *Pain* 1976;2:175–84.
73. Sen MK, Miclau T. Autologous iliac crest bone graft: should it still be the gold standard for treating nonunions? *Injury* 2007;38(Suppl. 1):S75–80.
74. Thor A, Franke-Stenport V, Johansson CB, Rasmusson L. Early bone formation in human bone grafts treated with platelet-rich plasma: preliminary histomorphometric results. *Int J Oral Maxillofac Surg* 2007;36:1164–71.
75. Urist MR. Bone: formation by autoinduction. *Science* 1965;150:893–9.
76. Vaibhav B, Nilesh P, Vikram S, Anshul C. Bone morphogenetic protein and its application in trauma cases: a current concept update. *Injury* 2007;38:1227–35.
77. Veillette CJ, McKee MD. Growth factors—BMPs, DBMs, and buffy coat products: are there any proven differences amongst them? *Injury* 2007;38(Suppl. 1):S38–48.
78. Weibrich G, Gnoth SH, Otto M, et al. Growth stimulation of human osteoblast-like cells by thrombocyte concentrates in vitro. *Mund Kiefer Gesichtschir* 2002;6:168–74.
79. White AP, Vaccaro AR, Hall JA, et al. Clinical applications of BMP-7/OP-1 in fractures, nonunions and spinal fusion. *Int Orthop* 2007;31:735–41.
80. Wozney JM. Bone morphogenetic proteins. *Prog Growth Factor Res* 1989;1:267–80.
81. Wrotniak M, Bielecki T, Gazdzik TS. Current opinion about using the platelet-rich gel in orthopaedics and trauma surgery. *Ortop Traumatol Rehabil* 2007;9:227–38.